

Original Article - Prospective Study

# Modification of mandibular ridge splitting technique for horizontal augmentation of atrophic ridges

Access this article online

Website:

[www.amsjournal.com](http://www.amsjournal.com)

DOI:

10.4103/2231-0746.133066

Quick Response Code:



Jawad A. Abu Tair

Department of Oral and Maxillofacial Surgery, Dental School,  
Arab American University, Jenin, Palestinian Authority, Jerusalem, Israel

Address for correspondence:

Dr. Jawad A. Abu Tair, Department of Oral and Maxillofacial Surgery,  
Dental School, Arab American University, Jenin, West Bank, Palestinian Authority,  
P.O. Box 73200, East Jerusalem 97970, Jerusalem, Israel.  
E-mail: [djawadat@gmail.com](mailto:djawadat@gmail.com)

## ABSTRACT

**Purpose:** A two stage approach of ridge splitting and lateral expansion in the mandible to achieve enough bone width for the purpose of dental implants is presented. **Materials and Methods:** A total of 13 consecutive patients with 16 long-span edentulous areas of the mandibular ridge were included in this study and 42 dental implants were inserted. Corticotomy of a rectangular buccal segment was carried out followed by 3 weeks of recovery; the mandibular ridge was stretched laterally, leaving the buccal periosteum attached to the lateralized segment. In this modification, there was no need for the use of grafted foreign materials to fill the defect and neither the use of barrier membranes, since it was treated practically as a fresh extraction site. To prevent the undesirable movement of the lateral plate, a small chip (2-3 mm in diameter) of bone spacer was properly fixed. The dental implants were placed 3-5 months later on. **Results:** Approximately, 86% of the expanded areas were successful in providing an adequate width to accommodate an implant. The average gain in width was  $3.22 \pm 0.97$  mm. All intended implants were inserted. Prosthetic loading with fixed prosthesis was successfully implemented in all cases. **Conclusion:** This modified technique is a simple and short procedure with satisfactory results and minimal morbidity. Of note, this approach is devoid of foreign materials usage and has a low rate cost, therefore, should be employed more often.

**Keywords:** Bone augmentation, dental implants, ridge expansion, ridge osteotomy, ridge splitting

## INTRODUCTION

Insufficient bone thickness of an atrophic mandible ridge is a common problem for situating screw-type dental implants. Narrow edentulous alveolar ridge of 4 mm or less requires horizontal augmentation. Several surgical techniques have been mentioned in the literature: Guided bone regeneration,<sup>[1-3]</sup> onlay block bone grafting,<sup>[4-6]</sup> ridge split technique or ridge expansion<sup>[7-10]</sup> and distraction osteogenesis.<sup>[11,12]</sup>

The aim of this ridge expansion approach is to create a new implant bed following two stages: (1) A full-thickness mucoperiosteal flap is elevated on the buccal aspect of the ridge. A saw, bur, or piezosurgical device is used to perform the apical horizontal, crestal, proximal and distal vertical corticotomies. (2) The second surgery, a month later, involves the splitting and

expansion of the ridge using osteotomes. At this stage, no buccal mucoperiosteal flap is elevated to preserve the vascularity of the buccal cortical plate. Fixation of the space between the buccal and lingual cortical plates is done, so blood clot fills the gap between the bone plates resembling a fresh extraction site. The implant placement is done 3-5 months later.

This study demonstrates the beneficial usage and outcome of the modified lateral ridge expansion technique.

## MATERIALS AND METHODS

This retrospective analysis follows the Declaration of Helsinki on medical protocol and ethics. As a retrospective study, there was no need for institutional review board approval and it was exempted.

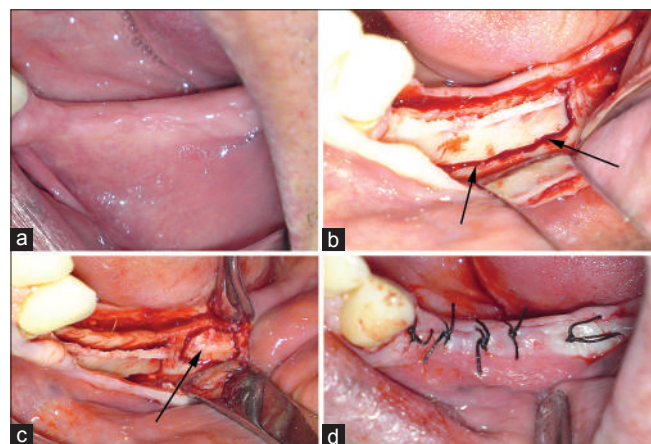
Medical records were reviewed of 13 patients undergoing ridge expansion surgery between the years 2007 and 2009 in Oral and Maxillofacial surgery clinic. In total, sixteen long span edentulous areas of the mandibular ridge were included in this study. In all cases, the preoperative bucco-lingual width of the bony ridge was between 2 and 4 mm at most. All had an adequate bone height for implant positioning. The technique of choice was similar to those used for ridge splitting in conventional dentoalveolar surgery with preference for staged protocol. Consequently, this procedure required a minimum of 2 appointments, with a gap of 1 month recovery period and check-ups. All treatment sessions were done under local anesthesia of 2% of Lidocaine and 1:100,000 Epinephrine.

### Surgical technique

#### Stage 1

A lateral mucoperiosteal flap was designed and performed by a midcrestal incision and when required, a vertical release incision was done for ease of access [Figure 1]. For the purpose of protection and isolation during the osteotomy, we exposed the lateral side of the ridge to a height of at least 10 mm. If the mental nerve was seen in the disclosed area during practice, it was exposed and protected as well. In literature,<sup>[13]</sup> corticotomies can be performed using a No. 15 blade, Beaver blade, razor-sharp chisel, round bur, fissure bur, diamond disk, reciprocal saw, or piezoelectric device. On high-density bone such as the mandible, the rotary bur, diamond disk, piezoelectric device or laser (erbium: Yttrium-aluminum-garnet, erbium, chromium-doped: Yttrium-scandium-gallium-garnet) is recommended.

Corticotomies in this study were all carried out using a thin fissured high speed bur splitting the rectangular lateral cortical bone plate from all sides [Figure 1b]. Thus, making it possible for the lateral cortical plate to be loosened and even detached off its bed. Deeper parts of the dense bone in the area were cut using osteotomes.



**Figure 1:** (a) The width of a lower left ridge, which was to be augmented for future dental implants. (b) Corticotomy site in base of buccal plate (arrow) and all around, is deep enough to split the whole buccal cortical bone plate from its bed. (c) A piece of bone (arrow) posterior to ridge splitting area, being prepared in the same session and left in place. It would be harvested easily during the second stage surgery to be used as a spacer. (d) Primary closure of soft-tissue. Left for healing a period of at least 3 weeks

Small bone chips are needed for the second surgery as a spacer, so it was prepared by Corticotomy around a small block of bone posterior and adjacent from the main surgery field. After preparing this piece, it was left in place for future harvesting [Figure 1c].

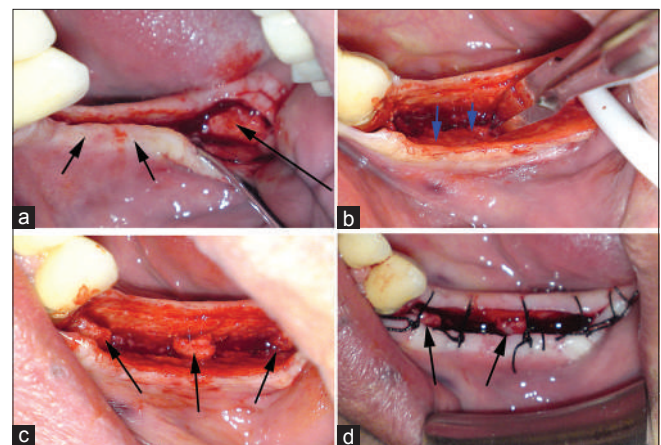
Once the plate was free, it was repositioned in place, covered by the mucoperiosteal flap and sutured without tension [Figure 1d]. Healing period was allowed for 3-4 weeks. The follow-up was 1 week later for suture removal and clinical evaluation.

#### Stage 2

This stage of the splitting was required for lateralization of the free cortical bone plate with the soft-tissue covering it, 3-5 mm laterally [Figure 2]. It was done by a midcrestal incision using osteotomes, without raising a mucoperiosteal flap [Figures 2a and b]. To prevent collapse back of the lateral plate, a small chip (2-3 mm in diameter) of bone spacer was inserted between the buccal lateralized segment and its bed [Figure 2c]. The spacer was collected from beside the ridge expansion area, mainly from the 3<sup>rd</sup> molar tooth or the retromolar area. This bone chip was prepared during the first session of treatment and was left in its place, only to be collected again in the second stage.

The outcome of this expansion resembles a fresh extraction socket, therefore, it was sutured using a black silk suture and left for bone clot to fill the space between the bone plates [Figure 2d]. Antibiotics were used in both stages of surgery: Amoxicillin (500 mg 3 times daily) for 5 days.

Clinical monitoring was carried out 1 week after surgery for suture removal, then 1 and 3 months post-surgery with visual examination of the healing tissues for any signs of inflammation. Furthermore, cone-beam computed tomography (CBCT) or an



**Figure 2:** (a) Second stage surgery (1 month later). Midcrestal incision is done without elevating a flap over the buccal cortical plate (short arrow). However, the bone needed to be harvested for use as a spacer is exposed (long arrow). (b) Expansion: Osteotome inserted in midcrestal incision and lateralization of the buccal segment (buccal cortical plate and covering soft-tissue), movement in the direction of arrows. (c) The bone harvested from the posterior area, was split to smaller pieces and inserted deep between the buccal and lingual bone plates, to prevent the collapse back of the lateralized segment. (d) The expanded ridge, sutured in place, looks like an extraction socket. The spacer (bone pieces) can be seen inside the gap (arrows)

orthopantomograph was carried out after 3-4 months, before implant insertion stage.

Three months at least were needed for bone healing. Removable partial prosthesis was not allowed to be used during the whole healing period.

Once the bone was properly regenerated, dental implants were inserted either by one stage or two stage surgery technique [Figures 3a and b]. At most, smoking was the main significant factor determining the two stage implantation.

A total of 16 ridge expansions procedures were conducted in 13 patients. The average gain in width was measured during the implant insertion surgery using a calibre of 1 mm intervals and by measuring on CBCT if available [Figures 4a-d]. An overall of 42 screw type dental implants (Biocom, MIS, Israel) were placed in the expanded ridges. The implants diameter varied between 3.3 mm (3 implants), 3.75 mm (20 implants) and 4.2 mm (19 implants) [Table 1].

In six cases, no enough bone width was gained at the area of the anterior vertical osteotomy. To overcome that; during the implant insertion, minor augmentation of the implant's exposed part has been made by means of autogenous bone particles, which were collected throughout the drilling for the implant bed preparation (in 6 implants; 14%).

Exposure of implants and prosthetic work-up commenced 3-5 months after the implant fixation (standard deviation =  $4.1 \pm 1.3$  months). Follow-up was carried out between 12 months and 43 months at most after the prosthetic loading [Figures 5a-c].

## RESULTS

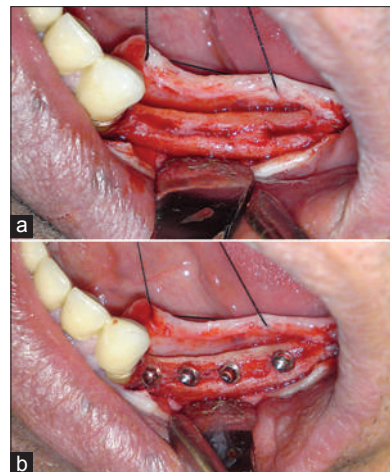
All buccal cortical bone plates were repositioned as planned at the basal corticotomy during ridge splitting. Bone width gain has been observed in all cases with an average width gaining of  $3.22 \pm 0.97$  mm, which varied between 2 and 5 mm. The secondary intentionally mucous membrane recovery phase obtained additional width of attached gingiva, similar to the healing of an extraction socket.

At 5 months following implants placement, all implants found to be physically stable and periapical X-rays showed no pathology around them hence, prosthetic loading with fixed prosthesis was successfully implemented in all cases.

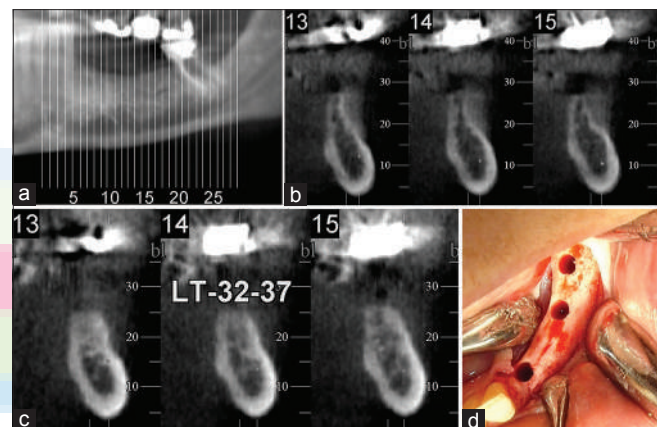
Of note, few complications included: Minor infections and exfoliation of the spacer (bone chip) causing elongation of the recovery period (three cases) other complications were non-significant, such as: Temporary sensory changes in the lip and chin and minor loss of vertical dimension of the bony ridge.

About three and a half years after the prosthetic loading, until submission of this report, the clinical follow-up demonstrated successful implantation.

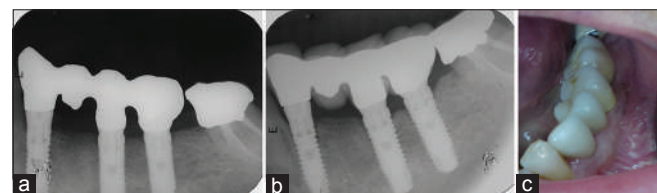
As previously described, minor loss of vertical dimension of the bony ridge was a complication noted in our study. Elevation of the



**Figure 3:** (a) Implant insertion stage: Enough ridge width for implant insertion. (b) Enough buccal and lingual bone. The area of previous anterior corticotomy (first premolar area) is compromised in bucco-lingual width, but still enough for implant insertion



**Figure 4:** (a) Another case demonstrates the left mandibular region. (b) Vertical computed tomography slices of the area just before splitting. (c) Vertical slices of the same area, (done by the same cone-beam computed tomography machine), 5 months after the second stage of ridge widening. The gain in width and also the loss of the ridge height can be discerned. (d) The prepared sockets for implantation in the wide ridge



**Figure 5:** (a) The prosthesis 2 months after its fabrication (of the case shown in Figures 3-5). (b) The follow-up radiograph 23 months after the bridge fabrication. (c) The follow-up 23 months after the bridge fabrication

mucoperiosteal flap and osteotomy at the crest of the bony ridge, seemingly caused this minor loss of ridge height. The difference in height loss of the bony ridge was measured in relevance to a fixed anatomical structure, such as: Inferior alveolar canal, mental nerve, or already existing roots of adjacent teeth. CT and panoramic X-ray were used for the comparison of the height loss. The average estimated loss in height was 2.47 mm.

**Table 1: The different cases in this study**

Patient no.	Gender/ age	Special consideration	No. of ridges	Sites of ridges	Bone width gained after the healing period (mm)	Time from second surgery to implant insertion (months)	Type of implant surgery. One stage/two stages	No. of implants inserted/ mean diameter (mm)	Follow-up from day of prosthesis (months)	Complications
1	M/65		2	Lt. mandibular second premolar and first molar	2-2.5	5.7	One stage	2/3.975	27	
2	M/43	Smoker	1	Mandibular incisors	1.5-2.5	5.7	One stage	2/3.525	27	Minor fenestration at body of the Lt. implant
3	F/46	Mental nerve in the path of osteotomy	1	Lt. mandibular first and second molars	3.5	3.5	Two stages	2/3.75	19	Bone spacer exfoliated
4	F/36	Mental nerve in the path of osteotomy	1	Lt. Mandibular canine until first molars	3 mm anterior and 5 mm posterior	3.5	Two stages	3/4.05	31	Non
5	M/30	Smoker	2	Rt. mandibular second premolar and first molar	2.5	5	First molar: One stage. Second premolar: Two stages	2/3.975	27	
6	F/45	Smoker. Full lower edentulous	2	Rt. mandibular molars	5	2	Two stages	2/4.2	31	Foreign body reaction against the spacer
7	F/59	Mental nerve in the path of osteotomy	1	Lt. mandibular molars	5	2	Two stages	2/4.2	43	Foreign body reaction against the spacer
8	F/61	Mental nerve in the path of osteotomy	2	Lt. mandibular edentulous ridge	3	3	Two stages	4/4.2	22	Need longer healing time for bone to fill up
9	M/43	Smoker	1	Rt. mandibular edentulous ridge	3	3	Two stages	4/4.2	22	Need longer healing time for bone to fill up
10	M/39	Smoker	1	Lt second premolar and molars	2	4	One stage	3/3.75	37	
11	F/22	Smoker	1	Rt. second premolar and molars	3 mm anterior and 5 mm posterior	4.2	2 molars one stage. Premolar as one stage	3/4.05	20	Temporary paresthesia of lip related to implant insertion
12	M/48		1	34, 35	3	4	Two stages	2/3.75	31	Labial bone fenestration during implant insertion in place of left first premolar, augmented during implant insertion
13	F/34		1	34, 35, 36, 37	2 anterior and 4 posterior	5.5	Two stages	4/3.75	12	Labial bone fenestration during implant insertion in place of left first premolar, augmented during implant insertion
14	F/22	Smoker	1	45, 46	3	6	Two stages	2/3.75	12	Labial bone fenestration in place of lower right second premolar, augmented during implant insertion from autogenous bone collected during drilling also epulis granulomatousum in bone spacer area
15	M/48		1	34, 35, 37	2 mm all over	4	Two stages	3/3.45	12	Labial bone fenestration during implant insertion in place of left first and second premolar, augmented during implant insertion
16	F/34		1	35, 36	3 mm all over	5	Two stages	2/3.975	26	Labial bone fenestration during implant insertion in place of left first premolar, augmented during implant insertion

Rt. = Right, Lt. = Left

## DISCUSSION

Ridge splitting and expansion of the mandible is rarely discussed in English medical literature.<sup>[14]</sup> The lateral ridge expansion technique is more suitable to be carried out on the maxilla rather than on the mandible, chiefly, due to the thinner maxillary cortical plates and soft medullary bone.<sup>[15]</sup> As discussed by Jensen *et al*,<sup>[16]</sup> Marginal bone stability in relation to the diverse types of flaps, out of 65 different ridges studied, only nine cases concerned the mandible. Jensen *et al*. indirectly demonstrates the rare usage of ridge splitting technique in the lower jaw compared to the upper, mainly due to the rigidity of the mandibular cortical bone.<sup>[16]</sup>

In the present study, in order to achieve a complete access to the buccal cortical plate, a full thickness flap was elevated, giving the possibility for a complete corticotomy. However, it cuts the blood supply from both the osseous base and the overlying periosteum. During the following 3-4 weeks of bone recovery, new angiogenesis is expected throughout the cortical plate, decreasing the possibility of complications when lateralizing it. Though, after the first and second intervention, the vascularization shifts to the periosteal external perfusion. The buccal cortical segment remained as a pedicle graft following the expansion of the ridge splitting (the second stage). This had been clarified by Enislidis *et al*.<sup>[14]</sup>

Until date, one cannot control the high incidence of greenstick fractures in the mandible resulting from single stage ridge splitting with osteotomes, due to its thickened cortical bone.<sup>[14,15]</sup> With this approach, the location of the osteotomy was pre-surgically determined and corticotomy was done all around the buccal cortical bone including the spongy bone, thus, reducing the chance of uncontrollable green stick fracture.

In a case report by Kheur *et al*. in "staged ridge splitting technique for horizontal expansion in mandible," the ridge was expanded and bone graft ossify containing biphasic beta tricalcium phosphate and hydroxyapatite was placed to maintain the gap between the cortices.<sup>[17]</sup> In the present study, the bone plates were maintained in place by using small bone chips inserted deep in between the separated cortical plates and then the mucosa sutured from buccal to lingual to aid in fixing the lateralized plate in place. The gap was between 3 and 5 mm and was left to be filled with a blood clot giving the opportunity for normal wound healing resembling an extraction socket. Depending upon the fact that fresh extraction sockets in these areas are always wider than 5 mm and they heal by secondary intension without the need for bone grafting or using guided regeneration techniques.

Although there was a loss of height consecutive to corticotomy, as was mentioned, but the length of implants used ranged from 10 to 13 mm. According to a new study, the incident of successful implantation with short implants is not significantly lower than with longer ones. It's the cautious treatment planning that above all affects the success rate.<sup>[18]</sup>

This retrospective analysis characterizes the successful rare usage of the lateral ridge expansion technique in the mandible. Furthermore, our study demonstrates this modified procedure as

a simple and short practice with satisfactory results and minimal morbidity. Of note, this approach is devoid of foreign materials usage and has a low rate cost, therefore, should be employed more often.

## REFERENCES

1. Buser D, Bragger U, Lang NP, Nyman S. Regeneration and enlargement of jaw bone using guided tissue regeneration. *Clin Oral Implants Res* 1990;1:22-32.
2. Nowzari H, Slots J. Microbiologic and clinical study of polytetrafluoroethylene membranes for guided bone regeneration around implants. *Int J Oral Maxillofac Implants* 1995;10:67-73.
3. Chiapasco M, Abati S, Romeo E, Vogel G. Clinical outcome of autogenous bone blocks or guided bone regeneration with e-PTFE membranes for the reconstruction of narrow edentulous ridges. *Clin Oral Implants Res* 1999;10:278-88.
4. Vermeeren JI, Wismeijer D, van Waas MA. One-step reconstruction of the severely resorbed mandible with onlay bone grafts and endosteal implants. A 5-year follow-up. *Int J Oral Maxillofac Surg* 1996;25:112-5.
5. Pikos MA. Block autografts for localized ridge augmentation: Part II. The posterior mandible. *Implant Dent* 2000;9:67-75.
6. Cordaro L, Amade DS, Cordaro M. Clinical results of alveolar ridge augmentation with mandibular block bone grafts in partially edentulous patients prior to implant placement. *Clin Oral Implants Res* 2002;13:103-11.
7. Simion M, Baldoni M, Zaffe D. Jawbone enlargement using immediate implant placement associated with a split-crest technique and guided tissue regeneration. *Int J Periodontics Restorative Dent* 1992;12:462-73.
8. Scipioni A, Bruschi GB, Calesini G. The edentulous ridge expansion technique: A five-year study. *Int J Periodontics Restorative Dent* 1994;14:451-9.
9. Scipioni A, Bruschi GB, Calesini G, Bruschi E, De Martino C. Bone regeneration in the edentulous ridge expansion technique: Histologic and ultrastructural study of 20 clinical cases. *Int J Periodontics Restorative Dent* 1999;19:269-77.
10. Sethi A, Kaus T. Maxillary ridge expansion with simultaneous implant placement: 5-year results of an ongoing clinical study. *Int J Oral Maxillofac Implants* 2000;15:491-9.
11. Takahashi T, Funaki K, Shintani H, Haruoka T. Use of horizontal alveolar distraction osteogenesis for implant placement in a narrow alveolar ridge: A case report. *Int J Oral Maxillofac Implants* 2004;19:291-4.
12. Laster Z, Rachmiel A, Jensen OT. Alveolar width distraction osteogenesis for early implant placement. *J Oral Maxillofac Surg* 2005;63:1724-30.
13. Sohn DS, Lee HJ, Heo JU, Moon JW, Park IS, Romanos GE. Immediate and delayed lateral ridge expansion technique in the atrophic posterior mandibular ridge. *J Oral Maxillofac Surg* 2010;68:2283-90.
14. Enislidis G, Wittwer G, Ewers R. Preliminary report on a staged ridge splitting technique for implant placement in the mandible: A technical note. *Int J Oral Maxillofac Implants* 2006;21:445-9.
15. Misch CM. Implant site development using ridge splitting techniques. *Oral Maxillofac Surg Clin North Am* 2004;16:65-74, vi.
16. Jensen OT, Cullum DR, Baer D. Marginal bone stability using 3 different flap approaches for alveolar split expansion for dental implants: A 1-year clinical study. *J Oral Maxillofac Surg* 2009;67:1921-30.
17. Kheur M, Gokhale S, S S, Jambekar S. Staged ridge splitting technique for horizontal expansion in mandible-A case report. *J Oral Implantol* 2012; Epub ahead of print, PMID: 22906165.
18. Romeo E, Bivio A, Mosca D, Scanferla M, Ghisolfi M, Storelli S. The use of short dental implants in clinical practice: Literature review. *Minerva Stomatol* 2010;59:23-31.

**Cite this article as:** Abu Tair JA. Modification of mandibular ridge splitting technique for horizontal augmentation of atrophic ridges. *Ann Maxillofac Surg* 2014;4:19-23.

**Source of Support:** Nil, **Conflict of Interest:** None declared.